

## Successful Reversal of Complex Regional Pain Syndrome Type 1 of Both Upper Extremities in Five Patients

**Disclaimer:** This article has not been sponsored by any pharmaceutical or equipment company or institution. This article has not been previously published nor is under consideration for publication in any other journal either in whole or in part. The manuscript has been read and approved by all authors mentioned in the title page and is an honest representation of each author's work.

Dear Editor,

Bilateral complex regional pain syndrome (CRPS) appears to be unusual [1–5]. We report details of bilateral CRPS diagnosed by International Association for Study of Pain (IASP) criteria in five patients who presented with florid symptoms (more prominent in one extremity) that persisted despite physical therapy (PT) and medications (Figure 1). They were effectively treated with a novel multimodality treatment regimen (MMTR) developed from our experience in over a hundred patients of CRPS-1 in the last 10 years.

Documented details of the patients included pain severity on verbal rating scale (VRS) at rest and movements; motor features (dystonia and disabilities); swelling; redness; and temperature changes using skin thermometer. Objective details documented included range of motions (ROMs) from shoulder to distal interphalangeal (DIP) joint by goniometry and hand grip using dynamometer. This allowed scoring on disability of arm, shoulder, and hand (DASH) scale. Ultrasonography (USG) of the forearm muscles was performed pre and post MMTR (Figure 2).

Patients 1–4 were treated with MMTR comprising medication with highest tolerated dose of amitriptyline, pregabalin, and tramadol; stellate ganglion block (SGB) for the less affected extremity; continuous brachial plexus block (CBPB) for 4–5 weeks for the more affected extremity; dry needling (DN) and PT of muscles of both upper extremities. The fifth patient, unable to afford the cost of CBPB, was treated with SGB, DN, and PT in the more affected left extremity and only DN, PT in the right extremity.

SGB (done with triamcinolone 40 mg and 3 mL, 0.25% bupivacaine) and CBPB were performed under USG guidance in operating theatre under antibiotic cover. Nerve stimulator (Stimuplex®, B. Braun Medical, Melsungen, Germany, USA) confirmed the placement of a stimulating catheter (StimuCath®, Arrow International, Reading, PA, USA) that was subcutaneously tunneled.

CBPB was accomplished via 0.125% bupivacaine 1–2 mL/h infusion from a patient-controlled analgesia (PCA) pump (Ambit®, Sorenson Medical, Salt Lake City, UT, USA) for 21–38 days. Bolus of 3–4 mL of 0.125% bupivacaine, with 2-hour lockout interval, was programmed and could be activated for pain >3VRS during PT and DN. Patients went home with an antibiotic schedule and instructions for PCA pump use. Wound dressing and pump refill were done weekly.

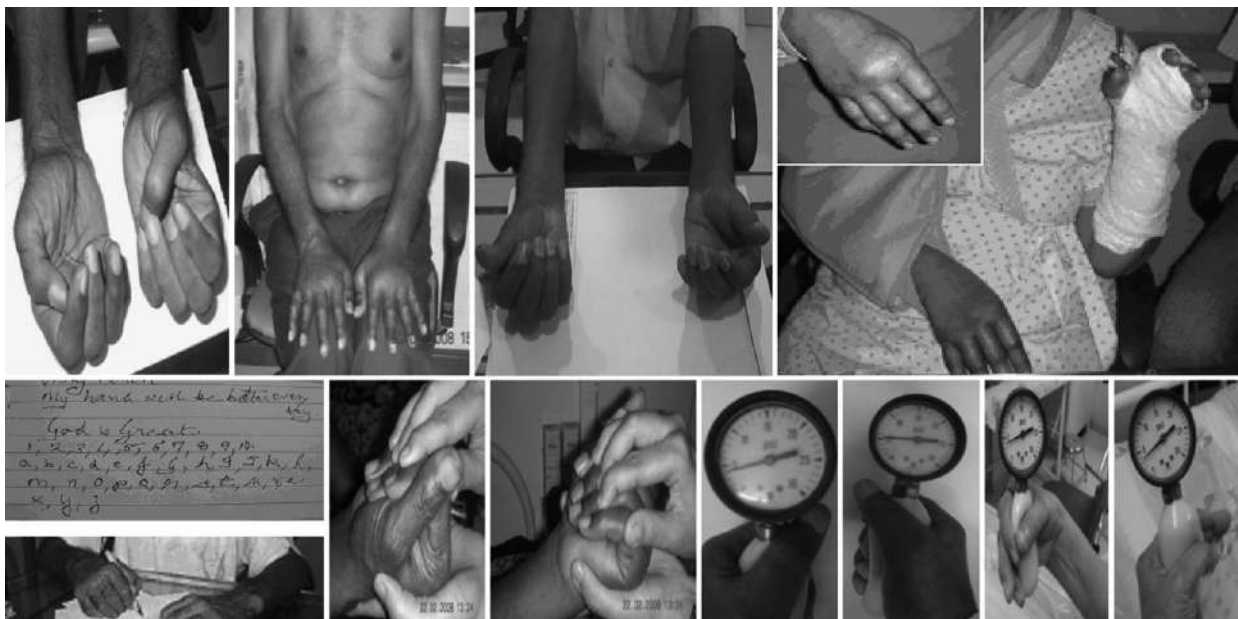DN of posterior neck muscles and extensor aspects of both extremities alternated with DN of pectorals and flexor aspect of both extremities for 40 days. DN involved slow, incremental advancement of 32 gauge, 25–50 mm long needles over 3–5 minutes. USG-guided DN was done for those specific muscles affected by the stiffness of CRPS. DN was followed by PT. Patients were followed up by telephone interviews up to 1 year.

### Results

SGB and CBPB improved pain, swelling, and warmth but not motor impairment. Paradoxically, warmth, redness, and swelling recurred intermittently up to 15 days especially after PT and daily activities. We documented a reduction of these symptoms as well as stiffness after each DN session. This enabled pain-free passive mobilization of the needled muscles. This improved the ROM by 4–5° at several joints. Needling of the digital extensors resulted in a marked improvement in finger flexion, whereas needling of the digital flexors improved finger extension. Patient 5 achieved relief of all symptoms with only DN for his right limb. Successive DN sessions led to a global motor improvement within 5 weeks coinciding with return of normal muscle architecture on USG (Figure 2). All patients progressed from total disability to complete motor recovery (DASH score reduction from 70–95 to 9–15). They continue to maintain their prior lifestyle to date.

### Discussion

Each component of MMTR served a specific purpose. SGB reduced pain, vasomotor, and sudomotor changes. CBPB continuously suppressed the same symptoms in the more affected extremity leading probably to reversal of neuronal plasticity. DN and PT, common to all the 10 limbs treated, appeared to specifically address the motor pathology of CRPS-1. DN relaxed the stiffness, making PT

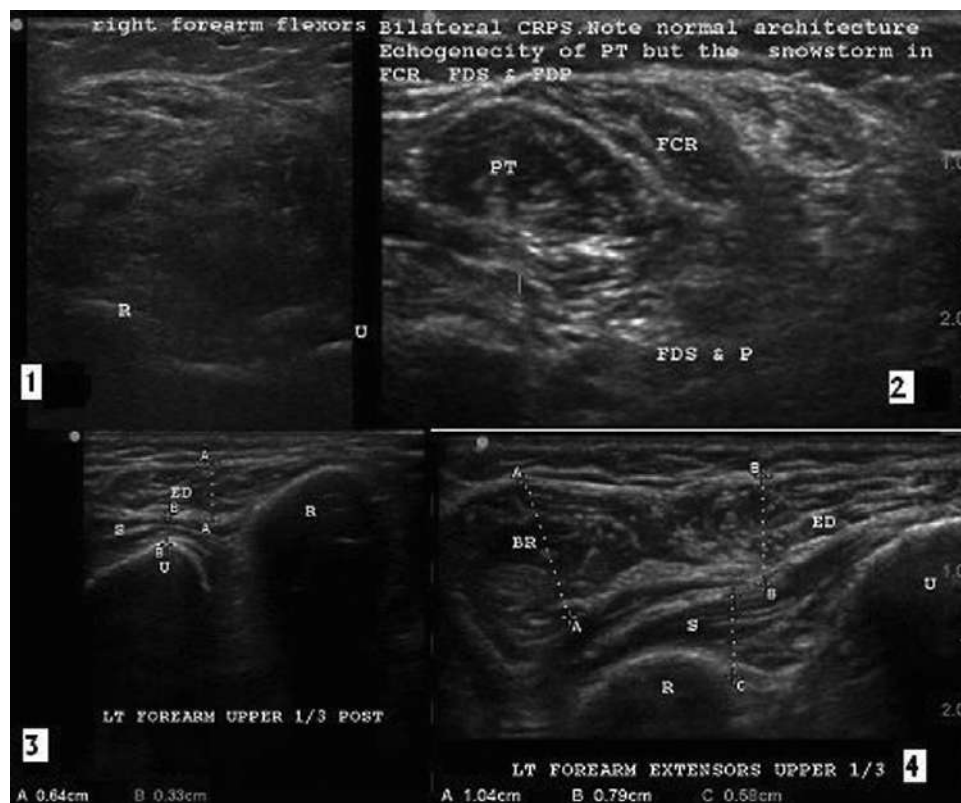


**Figure 1** (First row, left to right—figure of Patient 3 not included so as to maintain clarity of other figures.) *Patient 1*: 52-year-old man with bilateral claw hand. He had severe stiffness from fixed deformity that made writing, holding cups, cutlery, etc. impossible for 14 months after complex regional pain syndrome-1 (CRPS-1). Flexor and extensor muscle contractures were palpable as ropy strands and attempts to make a fist passively resulted in pressure allodynia. Note also the scars of sword injury that severed several tendons in both palms and forearms. He presented with 5–8 verbal rating scale (VRS) pain only on movement. Edema and hair growth (R > L). *Patient 2*: 72-year-old diabetic man had severe pain, sensory and motor features of CRPS-1 in both hands 4 months after a fall that resulted in soft tissue injuries; left more affected than right; complete disability, unable to get out of bed, and dress or feed himself; complete prostration. The man had severe rest pain (VRS 8–10) with hyperalgesia, allodynia, severe stiffness, weakness, dystonia, and abnormal movements (L > R). *Patient 4*: 60-year-old lady had plating done for right elbow fracture and external fixator put for left lower end radius fracture 5 months prior to presentation. The woman had severe rest pain (VRS 8–10), hyperesthesia, hyperalgesia, and allodynia, severe stiffness, and weakness. She had swelling, warmth, and color changes (R > L); confusion; disturbed sleep, complete disability, unable to get out of bed, dress or feed herself; and complete prostration. *Patient 5*: 51-year-old man presented with CRPS 8 months after multiple intramuscular trigger injections for pain and multiple intravenous injections on both upper limbs. He had severe pain on movement (VRS 8–10) and moderate rest pain (VRS 5–7); severe stiffness and weakness, swelling, cold to touch and color changes, point allodynia, muscle wasting; depressed, disturbed sleep, severe disability of volitional movements (L > R). *Bottom row*: The same patients at various stages of motor recovery. Patient 1 is writing at 5 weeks; patient 2 is making a complete fist 1 week after MMTR with some passive pressure from the physiotherapist. Patients could close their fingers over the dynamometer bulb by 1–2 weeks, although still unable to compress it. By 2–4 weeks (3 weeks in the less affected hand and 4 weeks in the better hand), their grip strength could generate 3–4 pounds per square inch of pressure. This figure shows patients 4 and 5 at 5 weeks.

effective. ROMs measured before and after DN showed a predictable and consistently reproducible increase.

CRPS-1 patients struggle to achieve any purposeful movement because of extreme motor stiffness. We

propose that this movement difficulty leads to strain on the digital flexor and extensor tendons that traverse snug fibrous tunnels along the fingers [6]. Attempts at movement provoke repeated friction and irritation between the tendons and their surrounding synovial sheaths, leading to



**Figure 2** USG of the more affected forearm of patient 4 (right flexors) and patient 5 (left extensors) before (images 1 and 3 on the left) and after treatment (images 2 and 4 on the right). Patient 4 had multimodality treatment regimen with continuous brachial plexus block, stellate ganglion block, dry needling, and physiotherapy. Patient 5 had only stellate ganglion block and dry needling. The images 1 and 3 on the left, documented at the first visit, show a mass of undifferentiated tissues with no delineation of fascicles, or even of the muscle itself. The complete destruction of structure makes it impossible to identify individual muscles. The images 2 and 4 on the right, documented at the end of the treatment, show a clear differentiation of hypoechoic muscle fascicles enveloped by hyperechoic fascia of a normal flexor and extensors.

inflammation inside these sheaths. This inflammation, seen as swelling, redness, and pain in fingers and hand affected by CRPS-1, is primary to the hand itself rather than a neurogenic inflammation as proposed previously [7].

Muscle relaxation by DN reduced the inflammation leading to temperature reduction as documented in all patients with skin thermometer. We attribute this effect to the muscle relaxation that reduced the movement-induced friction and inflammation. Muscle relaxation also reduced the excessive motor activity inherent to the spasm/stiffness/contracture, a hallmark of CRPS-1.

Pre-MMTR USG showed that the well-defined distinction between hypoechoic muscle fascicles enveloped by hyperechoic fascia of a normal muscle was lost in our patients and was replaced by uniformly hyperechoic fibrous tissue with no delineation of fascicles, or even of

the muscle itself [8]. Restoration of normal movements after successive DN sessions was accompanied by a gradual, discernible return toward the normal appearance of hypoechoic muscle fibers with hyperechoic septae on USG (Figure 2). In addition, USG demonstrated, in real time, the previously described response [9] of a painful muscle to needle introduction viz., the initial muscle twitch and flutter in response to needle introduction followed by quiescence that our patients described as relief of pain and reduction of stiffness. This has been described as a needle-induced reflex relaxation [9], probably mediated by inverse stretch reflex or Renshaw cell-mediated inhibition of extrafusal fibers [10].

To conclude, we propose that motor impairment is the primary feature of CRPS with the other manifestations like pain temperature and swelling being secondary to local inflammation. SGB and CBPB alleviated these secondary but clinically dominant features like pain warmth and

## Vas and Pai

swelling, while DN and PT addressed the primary motor pathology. Together, all these interventions (MMTR) were responsible for complete resolution of CRPS including disability, in this small cohort of five patients with bilateral CRPS (10 CRPS-affected limbs).

Sincerely,

LAKSHMI VAS, MD  
*Interventional Pain Management  
Ashirvad Institute for Pain Management and  
Relief Mumbai, India*

RENUKA PAI, Dip. Anaesthesia  
*Interventional Pain Management  
Ashirvad Institute for Pain Management and Research  
Mumbai, India*

## References

- 1 van Rijn MA, Marinus J, Putter H, et al. Spreading of complex regional pain syndrome: Not a random process. *J Neural Transm* 2011;118:1301–9.
- 2 Kozin F, McCarty DJ, Sims J, Genant H. The reflex sympathetic dystrophy syndrome. I. Clinical and histologic studies: Evidence for bilaterality, response to corticosteroids and articular involvement. *Am J Med* 1976;60:321–31.
- 3 Savafi S, Baloglu HH, Erifi S, Cerci S. Coexistence of complex regional pain syndrome type 1 and type 2 in a patient: A case report. *Turk J Phys Med Rehabil* 2010;March.
- 4 Baron JA, Zloty DM. Bilateral type 1 complex regional pain syndrome after local nerve blocks for palmar hyperhidrosis. *Dermatol Surg* 2009;35:885–7.
- 5 Yıldız N, Çdemiş Güngen G, Yaylalı O, Ardiç F. Bilateral complex regional pain syndrome associated with lumbar disc herniation. *Turk J Rheumatol* 2011;26:66–70.
- 6 Agur AMR, Dalley AF, eds. *Grant's Atlas of Anatomy*, 11th edition. Philadelphia, PA: Lippincott Williams & Wilkins; 2009:541.
- 7 de Mos M, Sturkenboom MC, Huygen FJ. Current understandings on complex regional pain syndrome. *Pain Pract* 2009;9:86–99.
- 8 Vas L, Pai R, Radhakrishnan M. Ultrasound appearance of forearm muscles in eighteen patients with complex regional pain syndrome type-1 of the upper extremity. *Pain Pract*. doi: 10.1111/j.1533-2500.2012.00539.x.
- 9 Gunn CC. Neuropathic myofascial pain syndromes. In: Bonica JJ, ed. *Management of Pain*, 3rd edition. Philadelphia, PA: Lippincott Williams & Wilkins; 2001: 522–9.
- 10 Ganong WF. Section III. Functions of the nervous system. In: Ganong WF, ed. *Review of Medical Physiology*, 20th edition. Los Altos, CA: Lange; 2001:126–7.