

Case Report

Complex Regional Pain Syndrome-Type 1 Presenting as deQuervain's Stenosing Tenosynovitis

Lakshmi Vas, MD, and Renuka Pai, Dipl Anesth

From: Ashirvad Institute
for Pain Management and
Research, Mumbai, India

Address Correspondence:
Dr. Lakshmi Vas
M.D Anesthesia
Ashirvad Pain Relief Clinic
Plot.No.117, ShubhAshirvad,
Road No. 5
Hindu Colony, Dadar East,
Mumbai – 400 014
E-mail:
lakshmi@paincareindia.com

Free full manuscript:
www.painphysicianjournal.com

Aim: To report the presentation of complex regional pain syndrome-1 (CRPS-1) as deQuervain's stenosing tenosynovitis (DQST).

Case report: A 24-year-old woman presented with 3-year history of clinical diagnostic criteria (CDC) of CRPS-1. Conservative and surgical treatment for this as DQST had failed to relieve her. We diagnosed the problem as CRPS-1 with CDC as inflammatory manifestations of a mechanical tendinosis of all her 5 digital tendons caused by movement of the fingers and hand tethered by agonist (flexor)/ antagonist (extensor) muscles in co-contraction. Ultrasound guided dry needling (USGDN) relaxed the muscles, replacing the abnormal agonist/antagonist co-contraction with normal agonist/antagonist coordination. Resolution of tendinosis reversed the inflammation causing the CDC. Six months later she leads normal personal and professional life, with reduction of scores of painDetect (from 21 to 5), Patient Health Questionnaire (from 13 to 4), Disability of arm, shoulder and hand from 70.8 to 25 and reversal of muscle abnormality characteristic of CRPS-1 on Musculoskeletal Ultrasonography (MSKUSG).

Conclusion: We believe the primary pathology of CRPS-1 to be co-contraction of agonist (flexor)/antagonist(extensor) muscles of digits resulting in tendinosis akin to DQST. CDC of CRPS are actually inflammatory manifestations of tendinosis amenable to reversal by USGDN which also addresses the disability, a hallmark of CRPS.

Key words: Complex regional pain syndrome-1 (CRPS-1), deQuervain's stenosing tenosynovitis (DQST), neuropathy, co-contraction, dry needling (DN), ultrasound guided dry needling (USGDN), musculoskeletal ultrasonography (MSKUSG)

Pain Physician 2016; 19:E227-E234

Complex regional pain syndrome type-1 (CRPS-1) is a progressive disease characterized by severe continuous pain, motor impairment, swelling, temperature and trophic changes in the distal part of an extremity. Clinical diagnostic criteria (CDC) are defined by International Association for Study of Pain (IASP), and modifications have been proposed (1,2). The pathophysiology (3-10), diagnostic investigations (11), and treatment remain uncertain (12-27). We have proposed in our previous publications (28-30) that the causative pathology of CRPS is the motor impairment. The main feature of motor impairment is a co-contraction of the agonist/antagonist muscles responsible for hand movements. Movement of the

fingers and hand tethered by the co-contracted muscle causes a mechanical tenosynovitis (or tendinosis as there is no infection). The inflammatory manifestations of this tenosynovitis/tendinosis are responsible for the pain, vasomotor, and sudomotor manifestations CDC of CRPS. Ultrasound guided dry needling (USGDN) as a specific treatment relaxes the co-contracted muscles. Resolution of co-contraction relieves the inflammatory manifestations of tenosynovitis/tendinosis resulting in a complete resolution of all the CDC of CRPS. We present in this report, a case that exemplifies the above surmise. CRPS that involved the thumb more than the other fingers was initially diagnosed as deQuervain's stenosing tenosynovitis (DQST). However, both

conservative and surgical treatment for DQST worsened the pain and disability. We treated the condition as CRPS with co-contraction. Resolution of co-contraction with USGDN reversed not only the co-contraction of the agonist/antagonist muscles responsible for the inflammatory mechanical tendinoses causing the CDC of CRPS but also the disability.

Case Report

A lady baker aged 24 years presented with positive Budapest Clinical Diagnostic Criteria. She had pain (6/10 at rest on numerical rating scale [NRS] [31] exacerbating to 10/10 on hand movements), sensory findings like stroke allodynia, hyperalgesia to light touch, pinprick, and cold > warmth over forearm (Fig. 1), 1° temperature increase and swelling (vasomotor and

sudomotor features). Motor findings included severe stiffness, heaviness, and flexion/extension restriction at wrist. Elbow movements were normal but painful. Shoulder flexion and abduction beyond 90° were painful. External and internal rotation also produced pain in the axillary folds in the end range of movement. Neck movements were restricted by pain (60° flexion/extension and 20 – 30° lateral flexion). She had no nail/hair changes. Her painDETECT score was 21 (a score of 18 – 38 has a > 90% likelihood of neuropathic pain) (32). Disability of arm, shoulder and hand (DASH) score was 70.8 (33) indicating considerable disability. Personal Health questionnaire (PHQ 9) was 13 indicating a major depressive disorder (34). She was unemployed for 3 years and had expressed suicidal ideation. Validity scale L of Minnesota Multiphasic Personality Inventory

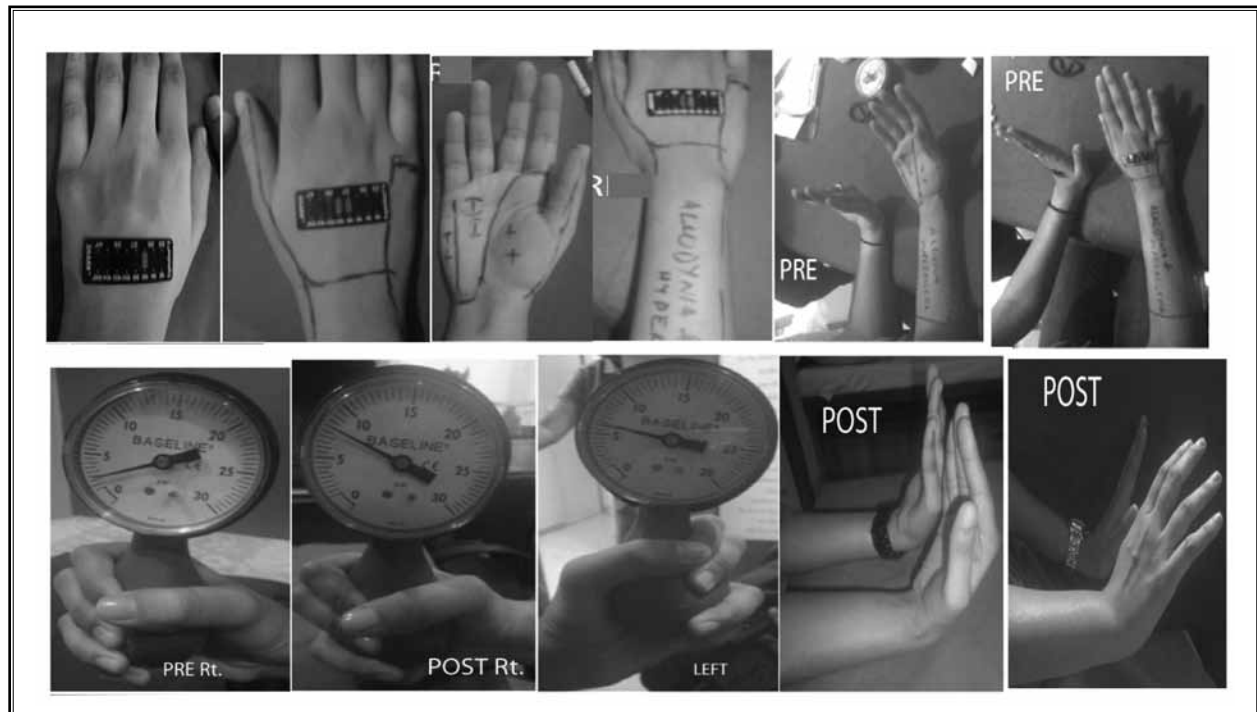


Fig. 1. Pre and post treatment clinical pictures.

Row 1: The right hand shows mild swelling and a temperature difference of 1° compared to the normal left hand. She had stroke allodynia, hyperalgesia to light touch, pinprick, and cold more than to warmth over the marked areas of distal 2/3 of forearm. The words “allodynia” and “hyperalgesia” on the patient’s right forearm were written after the first dose of midazolam + ketamine prior to DN. There was a definite response of flinching but she allowed it willingly and was quite coherent to indicate the areas to be marked. Care was taken to write very lightly. Movements were severely painful at all the joints of the thumb and moderately painful over the other fingers. Both flexion and extension were restricted at the wrist.

Row 2: Dynamometer reading of right hand was 2 pounds per square inch (psi) as compared to the 6 psi on left. But at 30 days the grip strength has increased to 3 psi. The measurements on this type of dynamometer give a lower reading as compared to the Jamar dynamometer but in this patient both the pre and post measurements were carried out with the same bulb dynamometer hence they reflect the true improvement in this patient. The flexion and extension at the wrist also has become normal.

(MMPI) score suggested a lack of honesty in answering the questionnaire to project a psychologically better adjusted personality (35). Musculoskeletal ultrasonography (MSKUSG) of the muscles of the CRPS affected right extremity was abnormal while the unaffected left upper extremity was obviously normal (Fig. 2).

Her symptoms had started 3 years prior, when she was 21 years with pain at the base of the second and third fingers after a bout of hand overuse as an apprentice baker (after shelling 2 kilos of walnuts). The pain and swelling progressed to the whole hand but mainly centered near the thumb. This remained unresponsive to physiotherapy and various analgesics prescribed by orthopaedic surgeons, rheumatologists, and psychiatrists over the next 2 years. Rheumatoid factor, C-reactive protein, and cyclic citrullinated peptide antibody were normal. Triple phase bone scan had suggested CRPS involving small joints of the right hand and wrist. Two consecutive steroid injections into the abductor and extensor tendons under ultrasound guidance had actually worsened her condition. Surgical release of the first extensor compartment 2 years later relieved her pain only for a month. Gradually over the next year, recurrent episodes of pain and stiffness had remained unresponsive to analgesics, neuromodulators (duloxetine, pregabalin, amitriptyline), and to 2 courses of oral steroids for 7 days with the dose tapered thereafter. She reported that there were intervals of reduced pain when she could use her hand minimally, but this would result in a flare up of activity-triggered pain, swelling, and warmth not only in the hand, but also the elbow and shoulder. At the time of presentation to us, the pain and disability had involved the whole of right extremity.

We explained to the patient about our concept of CRPS manifesting as mechanical tendinoses and the logic of treatment with USGDN. She refused stellate ganglion and continuous brachial block for pain relief but consented for USGDN with sedation. Possible complications of pain/heaviness during the USGDN and bruising and ecchymosis after USGDN were explained. She chose to defer psychological counseling for her depressive symptoms until after her pain was controlled. She attended 2 psychological counselling sessions one month after USGDN treatment but unilaterally decided that she did not need it.

USGDN specifically targeted the digital flexor/extensors and wrist, the pronator-supinators of the forearm, and the other proximal muscles of the right upper extremity (Fig. 3). Our protocol involved alternate day

needling but she was able to tolerate only twice weekly needling and that too with sedation. She required oral midazolam 2 mg with intranasal ketamine 25 mg to allow half the number of needles in the hyperalgesic and allodynic areas for the first 3 sessions of USGDN. Subsequently the hyperalgesia and allodynia disappeared and she could allow full complement of needles shown in Fig. 3, without ketamine. USGDN of the extensor aspect of the extremity and the neck alternated with USGDN of the flexor aspect of the limb and the pectoral muscles. The needles were introduced at 1 – 2 cm intervals along the length and at 1 cm intervals along the breadth of the muscle to the full depth of the muscle, as seen on USG (Figs. 3 and 4). Regular needling of the scar reduced the fibrosis tethering tendons abductor pollicis and the extensor pollicis brevis and restored suppleness to the scar (Fig. 4). Twice weekly USGDN was continued for a month and then once weekly until 45 days by which time she had complete recovery with increase in muscle bulk (Fig. 2). Subsequently the needling sessions were tapered off to fortnightly and then monthly sessions while she was asked to challenge her hand with increased activities (like manual preparation for baking bread > 5 kg cakes, playing carom etc.) to eliminate any residual disability. She continues with a normal professional life at 6 months with painDETECT score of 3, PHQ of 1, DASH of 6.3 (90%), and has presently gotten engaged to be married.

Discussion

This case presentation exemplifies our surmise that the movement difficulty of CRPS is primarily because of abnormally co-contracted digital flexor/extensors and that it is the basic pathology of CRPS. All the clinical manifestations that form the CDC of CRPS are actually manifestations of a global mechanical tendinoses of the flexor/extensors of all the fingers including the thumb. Our patient had originally presented at 21 years of age while the normal age of presentation of DQST is 30 – 55 years of age (36-41). One DQST survey shows an age category of greater than 40 as a rate of 2.0 per 1,000 person-years compared to 0.6 per 1,000 in persons under 20 years (40). The results of steroid injections in DQST are reported to be good for about 4 months (42,43) and DQST surgery also reports good results (44,45). Our patient's symptoms had worsened with both conservative and surgical treatment of DQST which had left the hand useless with a DASH score of 70.8 (33). It was only after recognition of the condition as a mechanical tendinoses resulting from the use of

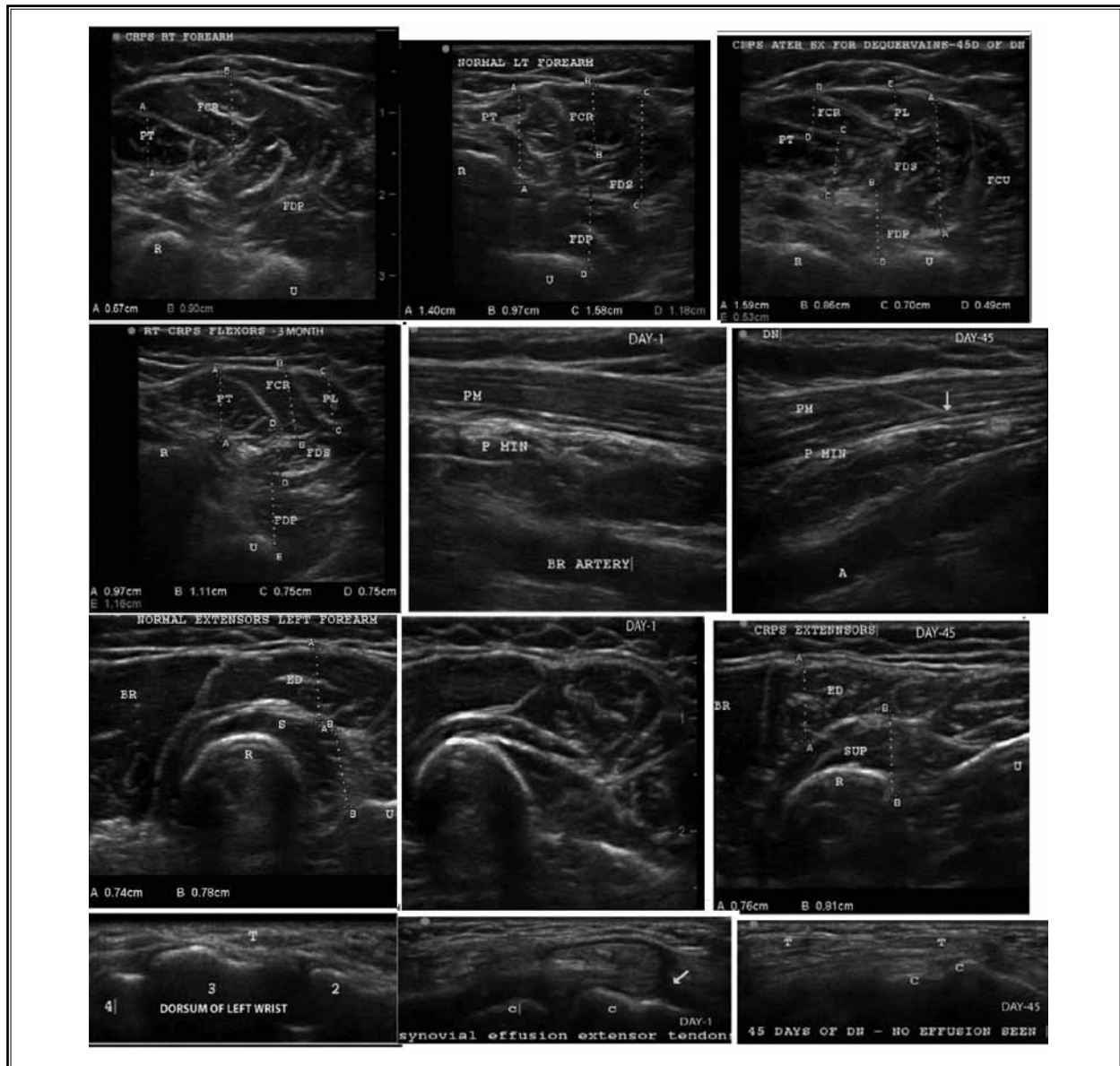


Fig. 2. Muscle ultrasonography shows the wasted muscles in the right extremity
 Row 1: The combined bulk of the flexor carpi radialis (FCR) and palmaris longus (PL) is 0.90 cm compared to the left hand FCR size of 0.97 cm. The pronator teres (PT) is 0.67 cm compared to the left hand PT which is 1.4 cm. The other muscles have indiscernible borders and hence were not measured. The features of wasting in CRPS differs from that of disuse in that muscle with disuse wasting have clear-cut muscle outlines, and the typical sonographic signature of a normal hypoechoic appearance with bright streaks of intramuscular septae. Whereas in CRPS patients like this, the muscle outlines are blurred and the contrast of hypoechoic muscle with hyperechoic septae becomes replaced by hyperechogenicity as seen in FCR and FDP. The same right hand after 45 days of dry needling shows an obvious increase in muscle bulk as well as the return of definition to muscles. Pronator teres size has increased to 0.70 cm and FCR and PL together measure $0.49 + 0.53 = 1.2$ cm. The flexor digitorum superficialis (FDS 1.59 cm) and flexor digitorum profundus (FDP 0.86 cm) are well defined. R: radius; U: ulna; FCU: flexor carpi ulnaris.
 Row 2: The first image show the sustained increase in size of flexors at 3 months. The second image shows the hyperechogenicity of pectoralis minor (P MIN) which has become normal by 45 days. PM: pectoralis major; BR ARTERY: brachial artery.
 Row 3: Shows the extensors. At 45 days, the extensors and supinators also show an increase in size. BR: brachioradialis; S: supinator; ED: extensor digitorum; SUP: supinator.
 Row 4: Shows the synovial effusion of the right hand extensors compared to the normal left hand tendons. The effusion around the extensor tendons has resolved by 45 days. 2, 3, 4: bases of the numbered metacarpals respectively; C: carpals; T: tendon

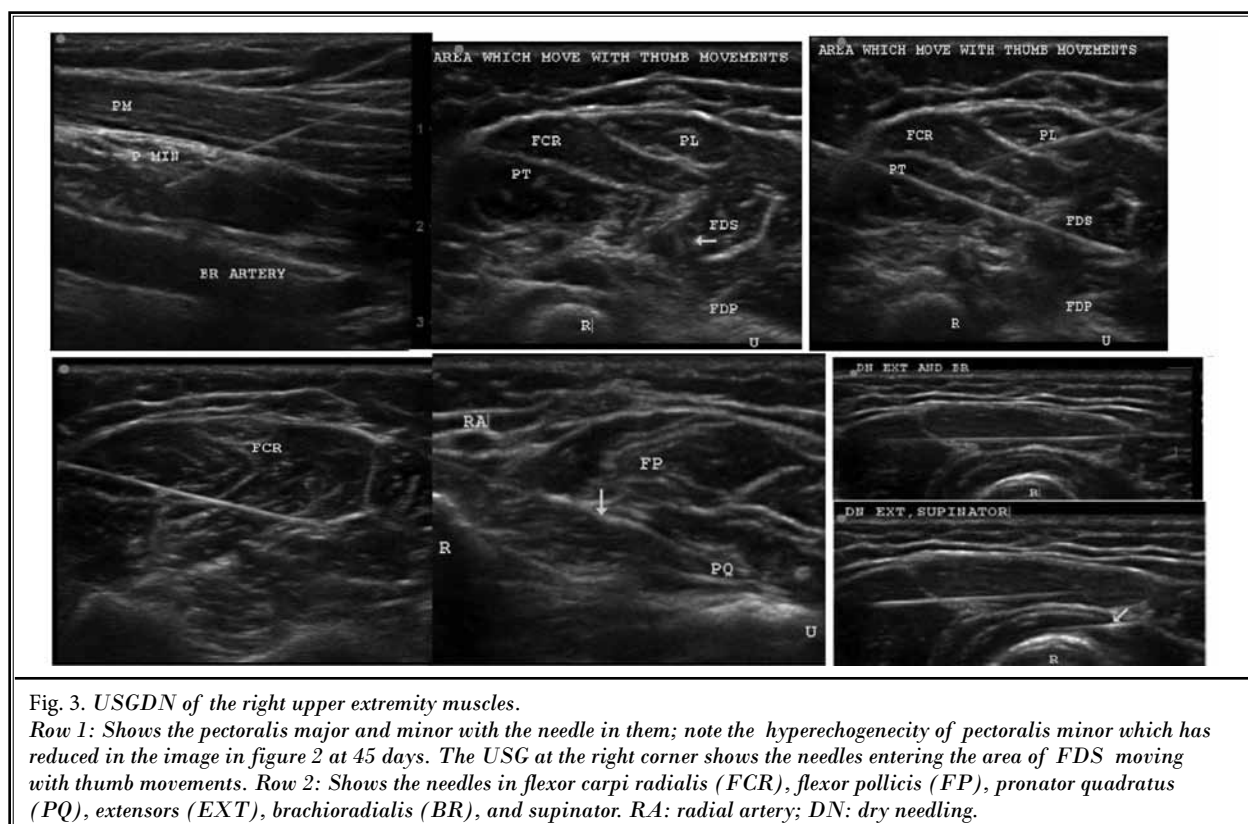


Fig. 3. USGDN of the right upper extremity muscles.

Row 1: Shows the pectoralis major and minor with the needle in them; note the hyperechogenicity of pectoralis minor which has reduced in the image in figure 2 at 45 days. The USG at the right corner shows the needles entering the area of FDS moving with thumb movements. Row 2: Shows the needles in flexor carpi radialis (FCR), flexor pollicis (FP), pronator quadratus (PQ), extensors (EXT), brachioradialis (BR), and supinator. RA: radial artery; DN: dry needling.

abnormally co-contracted flexor/extensors of CRPS that specific treatment with USGDN could reverse the motor impairment as well as the CDC of CRPS.

The simultaneous co-activation of both agonists and antagonists impedes all hand movements. Moving the constrained muscles leads to friction, inflammation, and mechanical tendinoses at all 5 digits. Dolor of inflammation causes severe pain and rubor and calor manifest as CDC. Persistent muscle nociception, tendinoses, and pain lead to peripheral and central sensitization leading to proximal extension of CRPS features.

Muscle nociceptive activity has been described in Myofascial Pain Syndrome (MPS) to activate dorsal horn neurons, causing central sensitization, hyperalgesia, and referred pain. Shortening of the contracted taut painful bands in muscles restricts movements. Impaired reciprocal inhibition results in co-contraction of agonists and antagonists, thus interfering with fine motor control and coordination. Autonomic disturbances like changes in skin temperature and color, and piloerection can accompany myofascial trigger point (MTrP) activation (46).

Once specific treatment with USGDN addressed the abnormally co-contracted flexor/extensors, her pain and motor impairment disappeared as well as the swell-

ing, warmth (within 10 days), and disability. DASH score became 25 (64.69% improvement) within 45 days, enabling her to return to her baking profession. The logic of USGDN was that it would relax both the groups of co-contracted muscles replacing the abnormal agonist/antagonist co-contraction with the normal agonist/antagonist coordination. The movements of the coordinated muscles are no longer impeded and thus, there would be little cause for friction at the flexor-extensor tendons. The tendinoses responsible for causing the CDC (warmth, swelling, color, nail and hair changes if present) would in turn disappear with resolution of the inflammation.

DN has been described as a specific treatment for MTrPs. Since DN appears to resolve the motor impairment of CRPS, it is logical to assume that MTrPs in both agonists and antagonists might be involved in the mediation of co-contraction. We have emphasized the role of the myofascial system in the causation of chronic post surgical pain through the mediation of motor neuropathy/neuromyopathy which also responds to USGDN (47).

The pathophysiology of MTrPs, the role of a compromised local blood supply, hypoxia, and acidosis at the MTrPs in causing muscle pain and dysfunction in

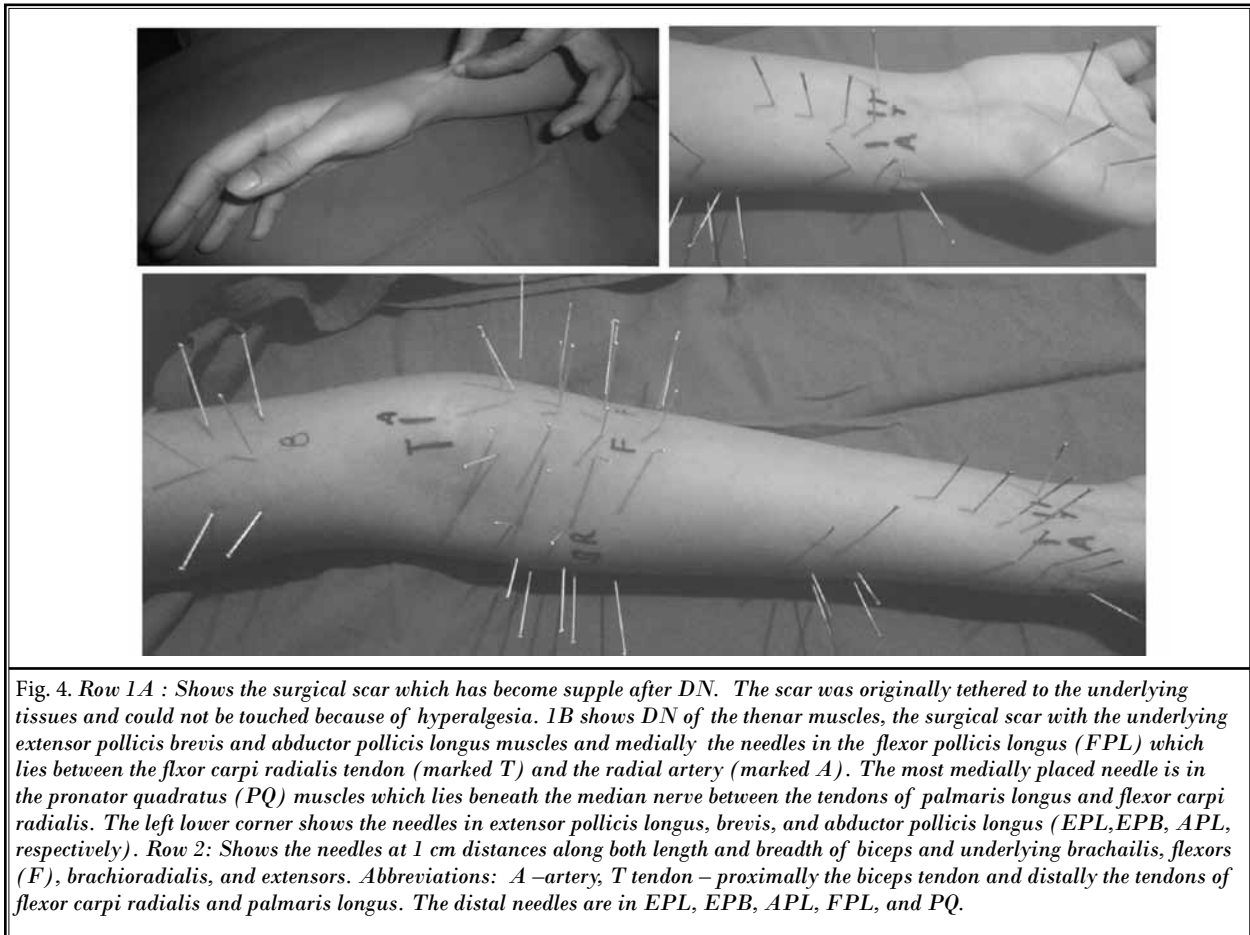


Fig. 4. Row 1A : Shows the surgical scar which has become supple after DN. The scar was originally tethered to the underlying tissues and could not be touched because of hyperalgesia. 1B shows DN of the thenar muscles, the surgical scar with the underlying extensor pollicis brevis and abductor pollicis longus muscles and medially the needles in the flexor pollicis longus (FPL) which lies between the flexor carpi radialis tendon (marked T) and the radial artery (marked A). The most medially placed needle is in the pronator quadratus (PQ) muscles which lies beneath the median nerve between the tendons of palmaris longus and flexor carpi radialis. The left lower corner shows the needles in extensor pollicis longus, brevis, and abductor pollicis longus (EPL, EPB, APL, respectively). Row 2: Shows the needles at 1 cm distances along both length and breadth of biceps and underlying brachialis, flexors (F), brachioradialis, and extensors. Abbreviations: A –artery; T tendon – proximally the biceps tendon and distally the tendons of flexor carpi radialis and palmaris longus. The distal needles are in EPL, EPB, APL, FPL, and PQ.

many chronic pain conditions is being increasingly accepted as is its reversal with DN (48-56). The scenario in CRPS of initial pain and dysfunction of inflammatory events and later ischemic events with contractures appears rather similar, but is distinguished by a rapid downhill course with actual loss of myoarchitecture on USG.

The hypothesis of co-contraction and tendinosis in CRPS is no doubt novel and unusual but is based on our clinical experience of uniform reversal with complete resolution of disability in 150 patients presenting in various phases of CRPS over the last 12 years (28-30). However, the concept of myofascial pain (MPS) in CRPS is not new. MPS has been reported in 61% of a series of 41 CRPS patients (57). EMG abnormality of antagonist co-activation has also been previously reported in CRPS (58). It is just that our hypothesis considers MPS as the initiating pathology that gives rise to all the other manifestations of CRPS. The severe pain of acute tendi-

nosis recruits the sympathetic response which eventually leads to sympathetic maintenance of pain. It is only after contractures develop in the co-contracted muscles to prevent movements of the hand that the tendinosis abates, to give rise to the cold extremity of very late CRPS. There are 2 reports on the histopathology of CRPS-1 affected muscles which report muscle fiber atrophy (59) with extensive changes in muscle tissue, such as fatty degeneration, fiber atrophy, and nuclear clumping, which was not related to duration of CRPS-I prior to amputation of the CRPS limb. Another reports only type 1 fiber atrophy and nerves showed no consistent abnormalities of myelinated fibers but in 4 patients, the C-fibers showed electron microscopic pathology (60).

MSKUSG provides objective information of loss of myoarchitecture and of effusion in the digital synovial sheaths. We propose a correlation between MSKUSG findings with movement difficulty, weakness, and stiff-

ness of CRPS. The vasomotor and sudomotor changes are actually a manifestation of inflammation in the tendinoses. In our experience, both stellate ganglion block (SGB) and continuous brachial plexus block (CBPB) are useful, but only for pain relief and neither procedure has any effect on motor impairment. Physiotherapy is often overwhelmed by the recurrence of pain and inflammation from the co-contraction which persists in spite of SGB and CBPB. But when DN is added, CRPS reversal becomes routine. However in patients with hyperalgesia CBPB/SGB/oral ketamine, midazolam analgesia have proven to be useful.

Conclusion

We propose that CRPS could be mistaken for DQST since both are tendinoses presenting with inflammation. The CDC of CRPS are actually inflammatory manifestations of multiple mechanical tendinoses secondary to an abnormal co-activation of the agonist/antagonist muscles of digital movements. This appears to resolve with USGDN which reverses the co-contraction, resulting in resolution of CDC as well as disability; thereby indicating a role for primary myofascial pathogenesis in CRPS.

REFERENCES

- Merskey H, Bogduk N. *Classification of Chronic Pain: IASP Task Force on Taxonomy*. 2nd edition. IASP Press, Seattle, 1994.
- Harden RN, Bruehl S, Stanton-Hicks M, Wilson PR. Proposed new diagnostic criteria for complex regional pain syndrome. *Pain Med* 2007; 8:326-331.
- Galer BS, Schwartz L, Allen RJ. Causalgia and other reflex sympathetic dystrophies. In: Bonica JJ (ed). *Management of Pain*. 3rd ed. Lippincott, Williams & Wilkin, Philadelphia, 2001, pp 388-411.
- Evans J. Reflex sympathetic dystrophy. *Surg Clin N Am* 1946; 26:780-790.
- Drummond PD. Mechanism of complex regional pain syndrome: No longer excessive sympathetic outflow? *Lancet* 2001; 358:168-170.
- Jänig W, Baron R. Complex regional pain syndrome is a disease of the central nervous system. *Clin Auton Res* 2002; 12:150-164.
- Oaklander AL, Fields HL. Is reflex sympathetic dystrophy/complex regional pain syndrome type I a small-fiber neuropathy? *Annals of Neurology* 2009; 65:629-638.
- Maihöfner C, Seifert F. Complex regional pain syndromes: New pathophysiological concepts and therapies. *European Journal of Neurology* 2010; 17: 649-660.
- Schwartzman RJ, Alexander GM, Grothusen J. Pathophysiology of complex regional pain syndrome. *Expert Rev Neurother* 2006; 6:669-681.
- Maihöfner C, Birklein F. Complex regional pain syndromes: New aspects on pathophysiology and therapy. *Fortschr Neurol Psychiatr* 2007; 75:331-342.
- Schürmann M, Zaspel J, Löhr P, Witzgall I, Tutic M, Manthey N, Steinborn M, Gradl G. Imaging in early posttraumatic complex regional pain syndrome: A comparison of diagnostic methods. *Clin J Pain* 2007; 23:449-457.
- Bruehl S, Harden RN, Galer BS, Saltz S, Backonja M, Stanton-Hicks M. Complex regional pain syndrome: Are there distinct subtypes and sequential stages of the syndrome? *Pain* 2002; 95:119-124.
- Stanton-Hicks M, Burton A, Bruehl SP, Carr D, Harden RN, Hassenbusch SJ, Lubenow TR, Oakley JC, Racz GB, Raj PP, Rauck RL, Rezaei AR. An updated interdisciplinary clinical pathway for CRPS: Report of an expert panel. *Pain Practice* 2002; 2:1-16.
- Sharma A, Williams K, Raja SN. Advances in treatment of complex regional pain syndrome. *Curr Opin Anaesthesiol* 2006; 19:566-572.
- Eisenberg E, Geller R, Brill S. Pharmacotherapy options for complex regional pain syndrome. *Expert Rev Neurother* 2007; 7:521-531.
- Nelson DV, Stacey BR. Interventional therapies in the management of complex regional pain syndrome. *Clin J Pain* 2006; 22:438-442.
- Cepeda MS, Carr DB, Lau J. Local anesthetic sympathetic blockade for complex regional pain syndrome. *Cochrane Database Syst Rev* 4:CD004598, 2005.
- Ribbers GM, Geurts ACH, Rijken RAJ, Kerkkamp HEM. Axillary brachial plexus blockade for the reflex sympathetic dystrophy syndrome. *Int J Rehabil Res* 1997; 20:371-380.
- Murray P, Atkinson R. Continuous axillary brachial plexus blockade for reflex sympathetic dystrophy. *Anaesthesia* 1995; 50:633-635.
- Wang L, Chen H, Chang P, Kang F, Tsai Y. Axillary brachial plexus block with patient controlled analgesia for Complex Regional Pain Syndrome type1: A case report. *Reg Anesth Pain Med* 2001; 26:68-71.
- Day M, Pasupuleti R, Jacobs S. Infraclavicular brachial plexus block and infusion for treatment of long-standing complex regional syndrome type 1: A case report. *Pain Physician* 2004; 7:265-268.
- Dadure C, Motais F, Ricard C, Raux O, Troncin R, Capdevila X. Continuous peripheral nerve blocks at home for treatment of recurrent complex regional pain syndrome I in children. *Anesthesiology* 2005; 102:387-391.
- Lee BH, Scharff L, Sethna NF. Physical therapy and cognitive-behavioral treatment for complex regional pain syndromes. *J Pediatr* 2002; 141:135-140.
- Goldberg ME, Domskey R, Scaringe D, Hirsh R, Dotson J, Sharaf I, Torjman MC, Schwartzman RJ. Multi-day low dose ketamine infusion for the treatment of complex regional pain syndrome. *Pain Physician* 2005; 8:175-179.
- Kiefer RT, Rohr P, Ploppa A, Altemeyer K, Schwartzman RJ. Complete recovery from intractable complex regional pain syndrome, CRPS-type I, following an-

- esthetic ketamine and midazolam. *Pain Pract* 2007; 7:147-150.
25. Taylor RS. Spinal cord stimulation in complex regional pain syndrome and refractory neuropathic back and leg pain/failed back surgery syndrome: Results of a systematic review and meta-analysis. *J Pain Symptom Manage* 2006; 31:13-19.
 27. Mailis-Gagnon A, Furlan AD, Sandoval JA, Taylor R. Spinal cord stimulation for chronic pain. *Cochrane Database Syst Rev* 3:CD003783, 2004.
 28. Vas L, Pai R, Radhakrishnan M. Ultrasound appearance of forearm muscles in eighteen patients with complex regional pain syndrome type - 1 of the upper extremity. *Pain Practice* 2013; 13:76-88.
 29. Vas L, Pai R. Successful reversal of complex regional pain syndrome type 1 of both upper extremities in five patients. *Pain Medicine* 2012; 13:1253-1256.
 30. Vas L, Pai R. Reversal of complex regional pain syndrome - type 2, and the subsequent management of complex regional pain syndrome - type 1 occurring after corrective surgery for residual ulnar claw. *Pain Medicine* 2014; 15:1059-1063.
 31. McCaffery M. Pain management: Problems and progress. In: McCaffery M, Pasero C. *Pain: Clinical Manual*. 2nd ed. Mosby, St. Louis, MO, 1999, p 16.
 32. Freynhagen R, Baron R, Gockel U, Tölle T. painDETECT: A new screening questionnaire to identify neuropathic components in patients with back pain. *Curr Med Res Opin* 2006; 22:1911-1920.
 33. Hudak PL, Amadio PC, Bombardier C. Development of an upper extremity outcome measure: The DASH (disabilities of the arm, shoulder and hand) [corrected]. The Upper Extremity Collaborative Group (UECG). *Am J Ind Med* 1996; 29:602-608. Erratum in: *Am J Ind Med* 1996; 30:372.
 34. Kroenke K, Spitzer RL, Williams JB. The PHQ-9: Validity of a brief depression severity measure. *J Gen Intern Med* 2001; 16:606-613.
 35. Bradley LA, McKendree-Smith NL. Assessment of psychological status using interviews and self-report instruments. In: Turk DC, Melzack R (eds). *Handbook of Pain Assessment*. Guilford, New York, 2001, pp 292-319.
 36. Moore JS. De Quervain's tenosynovitis. Stenosing tenosynovitis of the first dorsal compartment. *J Occup Environ Med* 1997; 39:990-1002.
 37. Finkelstein H. Stenosing tendovaginitis at the radial styloid process. *J Bone Joint Surg [Am]* 1930; 12:509-540.
 38. Muckart RD. Stenosing tendovaginitis of abductor pollicis longus and extensor pollicis brevis at the radial styloid (de Quervain's disease). *Clin Orthop Relat Res* 1964; 33:201-208.
 39. Lamphier TA, Crooker C, Crooker JL. De Quervain's disease. *Ind Med Surg* 1965; 34:847-856.
 40. Wolf JM, Sturdivant RX, Owens BD. Incidence of de Quervain's tenosynovitis in a young, active population. *J Hand Surg Am* 2009; 34:112-115.
 41. Johnson CA. Occurrence of de Quervain's disease in postpartum women. *J Fam Pract* 1991; 32:325-327.
 42. Peters-Veluthamaningal C, van der Windt DA, Winters JC, Meyboom-de Jong B. Corticosteroid injection for de Quervain's tenosynovitis. *Cochrane Database Syst Rev* 2009; 8:CD005616.
 43. Richie CA 3rd, Briner WW Jr. Corticosteroid injection for treatment of de Quervain's tenosynovitis: A pooled quantitative literature evaluation. *J Am Board Fam Pract* 2003; 16:102-106.
 44. Scheller A, Schuh R, Honle W, Schuh A. Long-term results of surgical release of de Quervain's stenosing tenosynovitis. *Int Orthop* 2009; 33:1301-1303.
 45. Lee H-J, Kim P-T, Iman WA, Han-Pyo H, Jong-Pil Y, In-Ho J. Surgical release of the first extensor compartment for de Quervain's tenosynovitis. *Clinics in Orthopedic Surgery* 2014; 6:2014.
 46. Mense SR, Gerwin RD (eds). *Muscle Pain: Diagnosis and Treatment*. Springer-Verlag, Berlin Heidelberg, 2010.
 47. Vas L, Khandagale N, Pai R. Successful management of chronic post-surgical pain following total knee replacement. *Pain Medicine* 2014; 15:1781-1785.
 48. Dommerholt J, Shah J. Myofascial pain syndromes. In: Ballantyne JC, Fishman SM (eds). *Bonica's Management of Pain*. 4th ed. Lippincott, Williams & Wilkins, Philadelphia 2010, pp 450-470.
 49. Hubbard DR, Berkoff GM. Myofascial trigger points show spontaneous needle EMG activity. *Spine* 1993; 18:1803-1807.
 50. Simmons DG. Do endplate noise and spikes arise from normal motor end plates? *Am J Phys Med Rehabil* 2001; 80:134-140.
 51. Maekawa K, Clark GT, Kuboki T. Intramuscular hypoperfusion, adrenergic receptors, and chronic muscle pain. *J Pain* 2002; 3:251-260.
 52. Bruckle W, Suckfull M, Fleckenstein W, Weiss C, Muller W. Gewebe-pO₂-Messung in deverspannten Rückenmuskulatur (m. erectorspinae). *J Rheumatol* 1990; 49:208-216.
 53. Sikdar S, Shah J. P, Gebreab T, Yen R-H, Gilliams E, Danoff J, Gerber LH. Novel applications of ultrasound technology to visualize and characterize myofascial trigger points and surrounding soft tissue. *Arch Phys Med Rehabil* 2009; 90:1829-1838.
 54. Shah JP, Danoff JV, Desai MJ, Parikh S, Nakamura LY, Phillips TM, Gerber LH. Biochemicals associated with pain and inflammation are elevated in sites near to and remote from active myofascial trigger points. *Arch Phys Med Rehabil* 2008; 89:16-23.
 55. Shah JP, Phillips T, Danoff JV, Gerber L. Novel microanalytical technique distinguishes three clinically distinct groups: 1) subjects without pain and without myofascial trigger points; 2) subjects without pain and with myofascial trigger point; 3) subjects with pain and myofascial trigger point. *Am J Phys Med Rehabil* 2004; 83:231.
 56. Chen Q, Bensamoun S, Basford JR, Thompson JM, An KN. Identification and quantification of myofascial taut bands with magnetic resonance elastography. *Arch Phys Med Rehabil* 2007; 88:1658-1661.
 57. Rashiq S, Galer BS. Proximal myofascial dysfunction in complex regional pain syndrome: A retrospective prevalence study. *Clin J Pain* 1999; 15:151-153.
 58. Jankovic J, VanDerLinder C. Dystonia and tremor induced by peripheral trauma: Predisposing factors. *J Neurol Neurosurg Psychiatry* 1998; 51:1512-1519.
 59. Hulsman NM, Geertzen JH, Dijkstra PU, van den Dungen JJ, den Dunnen WF. Myopathy in CRPS-I: Disuse or neurogenic? *Eur J Pain* 2009; 13:731-736.
 60. van der Laan L, ter Laak HJ, Gabreëls-Festen A, Gabreëls F, Goris RJ. Complex regional pain syndrome type I (RSD): Pathology of skeletal muscle and peripheral nerve. *Neurology* 1998; 51:20-25.